

Bronchoscopic Diagnosis of Thyroid Cancer With Laryngotracheal Invasion

Eisuke Koike, MD; Hiroyuki Yamashita, MD, PhD; Shiro Noguchi, MD, PhD; Hiroto Yamashita, MD, PhD; Akira Ohshima, MD, PhD; Shin Watanabe, MD; Shinya Uchino, MD, PhD; Keisuke Takatsu, MD; Ryuichi Nishii, MD, PhD

Hypothesis: Some controversy exists concerning the appropriate surgical management for patients with thyroid cancer invading the laryngotracheal wall. We have used shaving of the wall when cancer invasion was confined to the perichondrium, and extensive resection when it invaded further. Preoperative assessment of the depth and length of laryngotracheal invasion is important when choosing an appropriate surgical procedure.

Design: Prospective study.

Setting: A Japanese center for thyroid diseases, where about 1400 thyroid operations are performed each year.

Patients: Of 171 patients with thyroid cancer who were surgically treated between January 1, 2000, and July 30, 2000, 37 were suspected to have laryngotracheal invasion on preoperative magnetic resonance imaging or ultrasonography.

Intervention: We used bronchoscopy to examine the 37 patients suspected to have laryngotracheal invasion.

Main Outcome Measure: Bronchoscopic findings (localized mucosal redness, telangiectasia, mucosal elevation, mucosal edema, and mucosal erosion) were compared with pathological results in the 30 patients who underwent curative resections. Seven patients were excluded because of palliative resections.

Results: Of the 18 patients without localized mucosal changes, we performed shaving of the laryngotracheal wall in 4 patients because we found laryngotracheal invasion during surgery. Shaving of the laryngotracheal wall was performed successfully in terms of obtaining a cancer-free margin. Twelve patients with localized mucosal redness required extensive resections. Other mucosal changes were found depending on the depth of cancer invasion.

Conclusion: Surgeons should perform extensive resections when encountering localized mucosal redness on bronchoscopy.

Arch Surg. 2001;136:1185-1189

DIFFERENTIATED thyroid cancer usually has a good prognosis; however, it sometimes invades the adjacent organs and causes death by asphyxia. The practice of complete resection of malignant tumors has improved local control and survival rates.¹⁻⁴ Among cases in which cancer spread, laryngotracheal extension has been reported in 35% to 60% of patients with locally invasive diseases.⁵⁻⁷ Preoperative assessment of laryngotracheal invasion is important when choosing the appropriate treatment. The surgical procedures used currently include shaving of the laryngotracheal wall and extensive resection (fenestration, segmental tracheal resection, and partial or total laryngectomy). The choice of procedure depends on several variables, such as patient age, histological type, and depth and extent of invasion.⁵⁻¹⁶ We have applied shaving of the laryngotra-

cheal wall for differentiated thyroid cancer invading the perichondrium and, when feasible, extensive resection for differentiated thyroid cancer with deeper invasion. Judging whether thyroid cancer invades deeper than the perichondrium of the trachea can be difficult to do during surgery. Therefore, it is important to make a correct preoperative assessment of the depth and length of laryngotracheal invasion.

We describe the cases in which we evaluated bronchoscopic findings of laryngotracheal invasion of thyroid cancer to predict the depth and length of invasion so that we could determine the appropriate surgical procedure. Although many reports^{8,14,16-18} document the preoperative evaluation of laryngotracheal invasion by computed tomography, magnetic resonance imaging (MRI), or bronchoscopy, none of these has comprehensively addressed the issue of determining surgical procedures.

From the Noguchi Thyroid Clinic and Hospital Foundation, Oita, Japan.

PATIENTS AND METHODS

PATIENTS

Between January 1, 2000, and July 30, 2000, 171 patients underwent surgery for thyroid cancer, and 16 (9.4%) of these had laryngotracheal invasion. There were 3 men and 13 women whose ages ranged from 33 to 84 years (mean, 60.8 years). The mean tumor size was 32.9 mm. We examined all 171 patients using MRI and ultrasonography (US). Selection criteria for bronchoscopy were based on either MRI or US findings. An unclear border between the thyroid tumor and the laryngotracheal wall or destruction of the laryngotracheal wall was defined as a positive sign of invasion. We suspected laryngotracheal invasion when deletion of the fat plane between the thyroid tumor and the laryngotracheal wall was seen. We used bronchoscopy to examine 37 patients in whom laryngotracheal invasion was diagnosed or suspected by MRI or US. Seven patients were excluded because complete resections of the thyroid tumor were not performed. Shaving of the laryngotracheal wall was performed in 4 patients in whom invasion was suspected during dissection; although bronchoscopic diagnosis in them was negative for laryngotracheal invasion. Extensive resection was performed in 12 patients in whom diagnosis by bronchoscopy indicated laryngotracheal invasion. Fourteen patients received no laryngotracheal resection because no invasion was found at operation. Other

organs (the esophagus, the recurrent laryngeal nerve, or the strap muscle) were resected in 10 patients. Demographic data, tumor stage, surgical procedure performed, and bronchoscopic findings of 16 patients with laryngotracheal invasion are presented in the **Table**.

BRONCHOSCOPY

Bronchoscopic examination with a BF 1T30 endoscope (Olympus Co Ltd, Tokyo, Japan) was done with patients under local anesthesia. Localized mucosal redness, telangiectasia, mucosal elevation, mucosal edema, or mucosal erosion were considered the signs of invasion. Laryngotracheal invasion was diagnosed when at least 1 of these mucosal changes was seen. Diffuse mucosal redness and telangiectasia caused by compression were not considered positive signs. In 30 patients, the preoperative bronchoscopic diagnosis was compared with pathological results.

PATHOLOGICAL STAGING

We adopted the pathological staging system for laryngotracheal invasion by thyroid cancer as reported by Shin et al¹⁹ (stage 0, no invasion; stage I, invasion limited to the external perichondrium; stage II, invasion between the rings or destroyed the cartilage; stage III, invasion extending through or between the cartilage into the lamina propria of tracheal mucosa; stage IV, tracheal mucosal invasion) (**Figure 1**).

Demographics, Tumor Stage, Surgical Procedures Performed, and Bronchoscopic Findings of 16 Patients With Laryngotracheal Invasion*

Patient No.	Age, y	Sex	Bronchoscopic Findings							BF Diagnosis	Surgical Procedure	Stage	Other Invasion
			Compression	Localized Redness	Telangiectasia	Edema	Elevation	Erosion					
1	33	F	-	-	-	-	-	-	-	Noninvasive	Shav	I	-
2	68	F	-	-	-	-	-	-	-	Noninvasive	Shav	I	N, Mus
3	65	F	+	-	-	-	-	-	-	Noninvasive	Shav	I	N, Eso
4	36	F	+	-	-	-	-	-	-	Noninvasive	Shav	I	Mus
5	73	F	-	+	-	-	-	-	-	Invasive	Seg res	II	N
6	73	F	+	+	+	-	-	-	-	Invasive	Fenest	II	Eso
7	65	F	-	+	-	-	-	-	-	Invasive	Seg res	III	-
8	79	M	-	+	-	-	-	-	-	Invasive	Fenest	III	-
9	66	F	-	+	+	-	-	-	-	Invasive	Seg res	III	Mus
10	58	F	+	+	+	-	-	-	-	Invasive	Seg res	III	-
11	69	F	+	+	+	-	-	-	-	Invasive	Seg res	III	-
12	65	M	+	+	-	-	+	-	-	Invasive	Seg res	III	N
13	72	F	+	+	-	-	+	-	-	Invasive	Laryng	III	N, Mus, Eso
14	44	M	+	+	-	+	+	-	-	Invasive	Laryng	III	-
15	38	F	+	+	+	-	-	-	-	Invasive	Seg res	IV	N
16	84	F	+	+	+	+	+	+	+	Invasive	Fenest	IV	N

*BF indicates bronchoscopy; Shav, laryngotracheal wall shaving; N, recurrent nerve; Mus, strap muscle; Eso, esophagus; Seg res, segmental resection; Fenest, fenestration; Laryng, laryngectomy; and plus and minus symbols indicate whether the bronchoscopic finding or evidence of other invasion was present or absent.

RESULTS

According to the classification by Shin et al,¹⁹ of 30 patients who underwent complete resections, 14 patients without laryngotracheal invasion were at stage 0. Four

patients in whom cancer cells were detected in the shaved materials, although they showed no macroscopic residual tumors, were at stage I. Two patients were at stage II, 8 were at stage III, and 2 were at stage IV. Of these 16 patients between stage I and stage IV, 14 had papillary

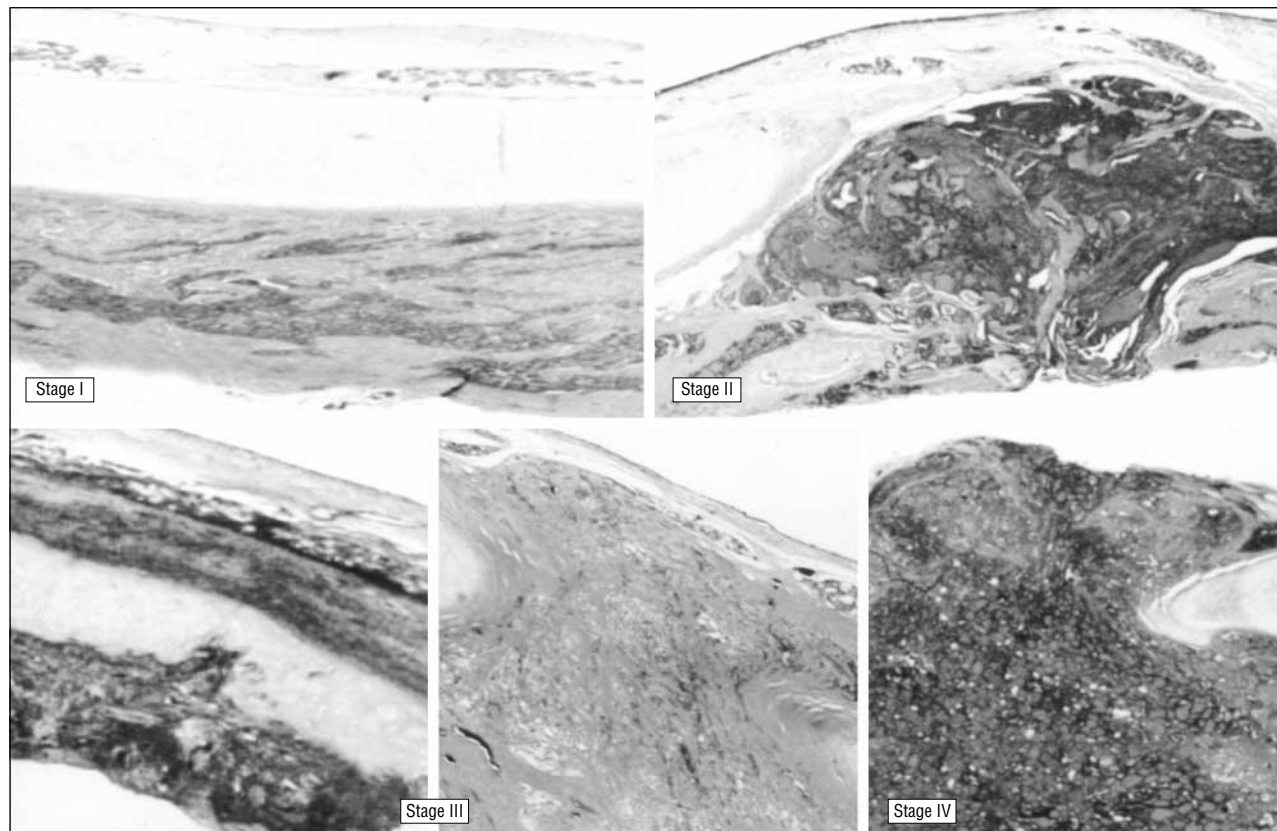


Figure 1. The staging system reported by Shin et al¹⁹ (stage 0, no invasion; stage I, invasion limited to the external perichondrium; stage II, invasion between the rings or destroyed the cartilage; stage III, invasion extending through or between the cartilage into the lamina propria of tracheal mucosa; stage IV, tracheal mucosal invasion). The top half shows the epithelium, and the bottom half shows the adventitia.

cancers, 1 had follicular cancer, and 1 had anaplastic cancer.

The diagnostic usefulness of bronchoscopy was evaluated by stages. Because of the lack of localized mucosal changes, no stage I patients were diagnosed as showing invasion. In contrast, all patients in stages II, III, and IV were correctly diagnosed as having laryngotracheal invasion. Typical bronchoscopic images from each stage are shown in **Figure 2**. Of 4 patients with stage I tumors, none showed localized mucosal changes of the larynx and trachea regardless of tumor compression. In 12 patients with tumors at stages II, III, or IV who required extensive resection, localized mucosal changes were always present in various degrees. Localized mucosal redness was seen in all patients with or without compression, and telangiectasia was occasionally seen in patients at each stage. Mucosal edema, elevation, and erosion were occasionally seen in patients at stages III and IV.

All patients with complete resections (except 1 patient with anaplastic cancer who died 5 months after surgery) were alive without recurrence at the time of this study.

COMMENT

Differentiated thyroid cancer usually has a good prognosis, particularly if the tumor is confined to the gland. Invasion of adjacent organs makes the prognosis unfavorable.^{1,8,20,21} Laryngotracheal invasion is common, ac-

counting for 35% to 60% of all locally invasive diseases,⁵⁻⁷ and it has been reported to occur in 3.7% to 12.4% of all thyroid cancers.^{8-10,18,22-24} Although complete resection of a malignant tumor improves local control and survival rate,¹⁻⁴ appropriate indications for either shaving the laryngotracheal wall or extensive resection for the laryngotracheal invasion is controversial.^{5-16,18,20,25-27} Czaja et al⁶ have applied extensive resection of thyroid cancers invading the laryngotracheal mucosa or submucosa, and shaving of the laryngotracheal wall for tumors invading only the laryngotracheal perichondrium. Several groups have agreed to this indication for determining surgical procedures.^{7,10-12,16} We also have applied these indications because we ascertained a cancer-free margin by intraoperative pathological diagnosis. Other groups did not advocate shaving of the laryngotracheal wall, but they did not discuss the depth of cancer invasion. Only Park et al¹⁸ concluded that extensive resection should be performed even if thyroid cancer invaded only the perichondrium.

To our knowledge to date, this is the first study to evaluate the bronchoscopic invasive signs of thyroid cancer by focusing on its depth and length as preoperative indicators for choosing an appropriate surgical treatment. Computed tomography scanning and MRI are useful for massive intraluminal involvement of thyroid cancer, but they seem to be of limited use for examining the depth and length of laryngotracheal invasion. Some authors have reported the usefulness of bronchoscopy for

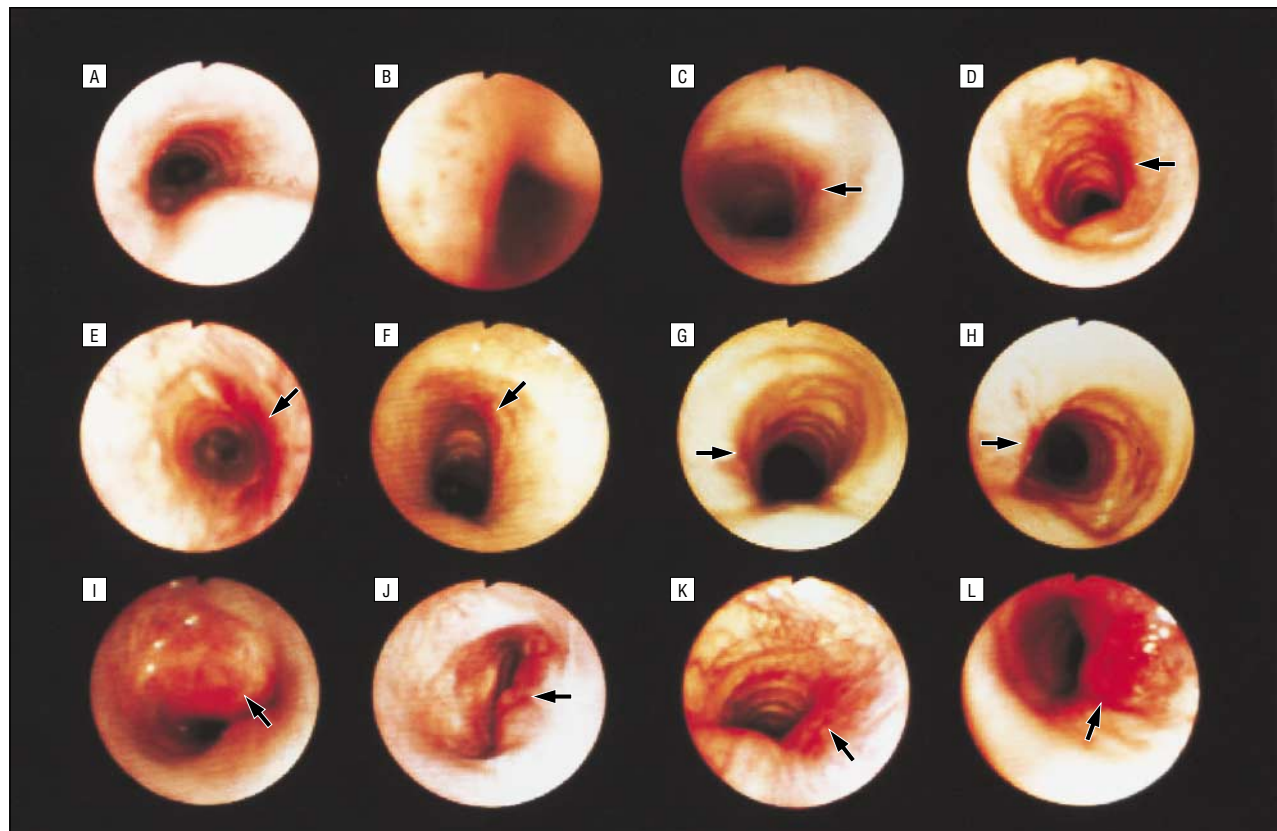


Figure 2. Typical bronchoscopic findings at each stage. A and B, stage I; C and D, stage II; E through J, stage III; and K and L, stage IV. The arrows show the invaded areas.

tracheal invasion with esophageal cancer.²⁸⁻³¹ Esophageal cancer invades the trachea from the posterior wall that lacks cartilage. Thyroid cancer usually invades the trachea between the rings of the cartilage. Therefore, the invasive signs of esophageal cancer on bronchoscopy cannot simply be applied as an invasive sign of thyroid cancer.

Localized mucosal change is an important sign of laryngotracheal invasion, especially localized mucosal redness. In stage I patients, the only mucosal change is diffuse mucosal redness caused by compression. In patients at stages II, III, and IV, localized mucosal redness always exists at various degrees, and this redness is stronger than that caused by compression. Histologically, the trachea consists of 4 layers: epithelium, lamina propria of mucosa, tracheal cartilage, and adventitia. The lamina propria of mucosa, which occupies a wide area under the epithelium and extends between the rings of the cartilage, is rich in blood and lymph vessels. Disturbance of blood and lymph flow by injury to the lamina propria induces mucosal changes such as redness, telangiectasia, and edema. Injury of the lamina propria by a large thyroid nodule is caused by strong compression on the tracheal cartilage, causing congestion and lymphostasis in the lamina propria, and resulting in diffuse mucosal changes. The injury to the lamina propria by thyroid cancer usually occurs between the rings of the cartilage, and only the invaded area shows congestion and lymphostasis resulting in localized mucosal changes.

Bronchoscopy is useful as a preoperative procedure for determining the appropriate surgical strategy for thyroid cancer invading the laryngotracheal wall.

Corresponding author: Hiroyuki Yamashita, MD, PhD, 6-33 Noguchi Nakamachi, Beppu, Oita, 874-0932 Japan (e-mail: yama@noguchi-med.or.jp).

REFERENCES

1. McConeahy WM, Hay ID, Woolner LB, vanHeerden JA, Taylor WF. Papillary thyroid cancer treated at the Mayo Clinic, 1946 through 1970: initial manifestations, pathologic findings, therapy, and outcome. *Mayo Clin Proc.* 1986;61:978-996.
2. Ishihara T, Kobayashi K, Kikuchi K, Kato R, Kawamura M, Ito K. Surgical treatment of advanced thyroid carcinoma invading the trachea. *J Thorac Cardiovasc Surg.* 1991;102:717-720.
3. Hay ID, Bergstralh EJ, Goellner JR, Ebersold JR, Grant CS. Predicting outcome in papillary thyroid carcinoma: development of a reliable prognostic scoring system in a cohort of 1779 patients surgically treated at one institution during 1940 through 1989. *Surgery.* 1993;114:1050-1058.
4. Dean DS, Hay ID. Prognostic indicators in differentiated thyroid carcinoma. *Cancer Control.* 2000;7:229-239.
5. Tovi F, Goldstein J. Locally aggressive differentiated thyroid carcinoma. *J Surg Oncol.* 1985;29:99-104.
6. Czaja JM, McCaffrey TV. The surgical management of laryngotracheal invasion by well-differentiated papillary thyroid carcinoma. *Arch Otolaryngol Head Neck Surg.* 1997;123:484-490.
7. McCaffrey TV, Bergstralh EJ, Hay ID. Locally invasive papillary thyroid carcinoma: 1940-1990. *Head Neck.* 1994;16:165-172.
8. Nakao K, Miyata M, Izukura M, Monden Y, Maeda M, Kawashima Y. Radical operation for thyroid carcinoma invading the trachea. *Arch Surg.* 1984;119:1046-1049.

9. Bayles SW, Kingdom TT, Carlson GW. Management of thyroid carcinoma invading the aerodigestive tract. *Laryngoscope*. 1998;108:1402-1407.
10. Segal K, Abraham A, Levy R, Schindel J. Carcinomas of the thyroid gland invading larynx and trachea. *Clin Otolaryngol*. 1984;9:21-25.
11. Nishida T, Nakao K, Hamaji M. Differentiated thyroid carcinoma with airway invasion: indication for tracheal resection based on the extent of cancer invasion. *J Thorac Cardiovasc Surg*. 1997;114:84-92.
12. Ballantyne AJ. Resections of the upper aerodigestive tract for locally invasive thyroid cancer. *Am J Surg*. 1994;168:636-639.
13. Yang CC, Lee CH, Wang LS, Huang BS, Hsu WH, Huang MH. Resectional treatment for thyroid cancer with tracheal invasion: a long-term follow-up study. *Arch Surg*. 2000;135:704-707.
14. Fujimoto Y, Obara T, Ito Y, et al. Aggressive surgical approach for locally invasive papillary carcinoma of the thyroid in patients over forty-five years of age. *Surgery*. 1986;100:1098-1107.
15. Ishihara T, Yamazaki S, Kobayashi K, et al. Resection of the trachea infiltrated by thyroid carcinoma. *Ann Surg*. 1982;195:496-500.
16. McCaffrey JC. Evaluation and treatment of aerodigestive tract invasion by well-differentiated thyroid carcinoma. *Cancer Control*. 2000;7:246-252.
17. McCaffrey TV, Lipton RJ. Thyroid carcinoma invading the upper aerodigestive system. *Laryngoscope*. 1990;100:824-830.
18. Park CS, Suh KW, Min JS. Cartilage-shaving procedure for the control of tracheal cartilage invasion by thyroid carcinoma. *Head Neck*. 1993;15:289-291.
19. Shin DH, Mark EJ, Suen HC, Grillo HC. Pathologic staging of papillary carcinoma of the thyroid with airway invasion based on the anatomic manner of extension to the trachea: a clinicopathologic study based on 22 patients who underwent thyroidectomy and airway resection. *Hum Pathol*. 1993;24:866-870.
20. Friedman M, Danielzadeh JA, Caldarelli DD. Treatment of patients with carcinoma of the thyroid invading the airway. *Arch Otolaryngol Head Neck Surg*. 1994;120:1377-1381.
21. Akslen LA, Haldorsen T, Thoresen SO, Glatre E. Survival and causes of death in thyroid cancer: a population-based study of 2479 cases from Norway. *Cancer Res*. 1991;51:1234-1241.
22. Talpos GB. Tracheal and laryngeal resections for differentiated thyroid cancer. *Am Surg*. 1999;65:754-760.
23. Batsakis JG. Laryngeal involvement by thyroid disease. *Ann Otol Rhinol Laryngol*. 1987;96:718-719.
24. Ebihara M, Ebihara S, Kishimoto S, et al. Surgical treatment of differentiated thyroid cancer with tracheal invasion [in Japanese]. *Nippon Jibiinkoka Gakkai Kaiho*. 1998;101:1406-1411.
25. Melliore DJ, Ben Yahia NE, Becquemin JP, Lange F, Boulahdour H. Thyroid carcinoma with tracheal or esophageal involvement: limited or maximal surgery? *Surgery*. 1993;113:166-172.
26. Britto E, Shah S, Parikh DM, Rao RS. Laryngotracheal invasion by well-differentiated thyroid cancer: diagnosis and management. *J Surg Oncol*. 1990;44:25-31.
27. Grillo HC, Suen HC, Mathisen DJ, Wain JC. Resectional management of thyroid carcinoma invading the airway. *Ann Thorac Surg*. 1992;54:3-10.
28. Choi TK, Siu KF, Lam KH, Wong J. Bronchoscopy and carcinoma of the esophagus, II: carcinoma of the esophagus with tracheobronchial involvement. *Am J Surg*. 1984;147:760-762.
29. Choi TK, Siu KF, Lam KH, Wong J. Bronchoscopy and carcinoma of the esophagus, I: findings of bronchoscopy in carcinoma of the esophagus. *Am J Surg*. 1984;147:757-759.
30. Watanabe A, Saka H, Sakai S, Hirao T, Hattori T, Shimokata K. Bronchoscopic and cytopathological findings of tracheobronchial involvement in esophageal carcinoma. *Endoscopy*. 1990;22:273-275.
31. Riedel M, Hauck RW, Stein HJ, et al. Preoperative bronchoscopic assessment of airway invasion by esophageal cancer: a prospective study. *Chest*. 1998;113:687-695.